

PATIENT

Lola Isakowitz

SPECIES

Canine

BREED

Yorkshire terrier Mix

SEX

FS

AGE

10 year

WEIGHT

18.8 #

INTERPRETED BY

Remo Lobetti, BVSc,
MMedVet (Med), PhD,
Dipl. ECVIM

IMAGING PERFORMED BY

Lara Wiseman, DVM

HOSPITAL NAME

Boca Midtowne Animal
Hospital

REFERRING VET

Dr Boazman

INVOICE

303430

DATE

9/24/22

PRESENTING CLINICAL SIGNS

History: Mild hepatomegaly, behavioral changes past 6 months – decreased energy and anxious when at home. Possible Cushing's disease

Physical Examination: N/A.

Urinalysis: N/A.

CBC: Normal.

Serum Biochemistry: Normal.

Radiographic Findings: N/A.

ULTRASONOGRAPHIC EXAMINATION OF THE ABDOMEN

Urinary System

Full urinary bladder with a normal thickness and echogenic appearance of the wall. Normal anechoic urine with no sediment or uroliths evident.

Normal trigone area, proximal urethra (0.3 cm), and iliac blood vessels.

Normal iliac lymph nodes. Ureters not visualized.

Normal renal size (both 4.4 cm) with increased echogenic appearance, some loss of cortico-medullary differentiation (left worse than the right) and normal capsule and right pelvis. Left pyelectasia (0.7 cm).

Reproductive System

N/A.

Adrenal Glands

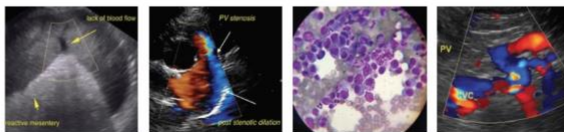
Normal shape, echogenic appearance, position, and size. Left 0.43 cm, right 0.41 cm.

Spleen

Normal size and echogenic appearance. Smooth homogenous parenchyma, regular curvilinear capsule, and normal vasculature. No evidence of inflammatory, neoplastic, infarction, or infiltrative changes noted.

Liver

Normal size, echogenic appearance, portal markings, and regular curvilinear capsule. No nodules or masses evident. Full gall bladder containing normal anechoic bile. Normal thickness and echogenic appearance of the gall bladder wall. Normal bile duct.



PATIENT

Lola Isakowitz

SPECIES

Canine

BREED

Yorkshire terrier Mix

SEX

FS

AGE

10 year

WEIGHT

18.8 #

INTERPRETED BY

Remo Lobetti, BVSc,
MMedVet (Med), PhD,
Dipl. ECVIM

IMAGING PERFORMED BY

Lara Wiseman, DVM

HOSPITAL NAME

Boca Midtowne Animal
Hospital

REFERRING VET

Dr Boazman

INVOICE

303430

DATE

9/24/22

Gastrointestinal

Normal appearance of the gastro-esophageal junction, stomach, duodenum, small intestine, ileo-cecal junction, and colon with no loss of layering, normal wall thickness (duodenum 0.41 cm, jejunum 0.35 cm) and peristaltic activity, and no distension of the lumen.

Pancreas

Normal size (right 1.5 cm) and echogenic appearance. Regular capsule. Normal echogenic appearance of the mesentery and fat surrounding the pancreas.

Free Abdomen

No mesenteric lymphadenomegaly.
No ascites.

ULTRASONOGRAPHIC FINDINGS

Primary findings:

- Renal disease?

Secondary findings:

- None.

INTERPRETATION OF THE FINDINGS & FURTHER RECOMMENDATIONS

Although the appearance of the kidneys may merely be age-related, with the pyelectasia, early chronic kidney disease and left sided pyelonephritis needs to be considered.

Further assessment would be urinalyses and urine culture.

Specific therapy would be dependent on an etiological diagnosis.



PATIENT

Lola Isakowitz

SPECIES

Canine

BREED

Yorkshire terrier Mix

SEX

FS

AGE

10 year

WEIGHT

18.8 #

INTERPRETED BY

Remo Lobetti, BVSc,
 MMedVet (Med), PhD,
 Dipl. ECVIM

IMAGING PERFORMED BY

Lara Wiseman, DVM

HOSPITAL NAME

Boca Midtowne Animal
 Hospital

REFERRING VET

Dr Boazman

INVOICE

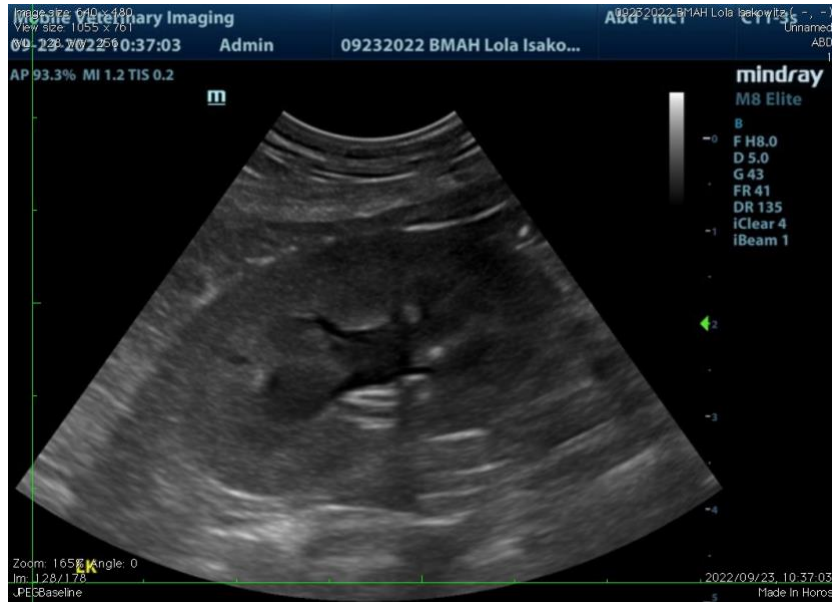303430

DATE

9/24/22

IMAGES

Left kidney



The information and recommendations provided are based on the images presented by the referring veterinarian. No evaluation can be communicated regarding pathology that was not visible in the image/video clips provided.

Thank you for this referral. If the clinical or image interpretation does not parallel your findings or if I can be of any further assistance please contact me.

Remo Lobetti, BVSc, MMedVet (Med), PhD, Dipl. ECVIM (Internal Medicine)
 rlobetti@mweb.co.za